



Current thinking on the role of interventional radiology in women's health

Jay Goldberg

Until the late 1990s, the primary reasons for obstetrician/gynecologists to involve interventional radiologists in the care of their patients were for pelvic/abdominal fluid collections and acute hemorrhage. Since 1995, an estimated 150,000 uterine fibroid embolizations (UFEs) have been performed. UFE improves fibroid-related bleeding and bulk symptoms, with low morbidity compared with hysterectomy. Patients requiring treatment who desire future fertility, especially those with distorted uterine cavities, are usually best served with myomectomy rather than UFE. Premyomectomy UFE for the massively enlarged uterus can decrease the risk of hemorrhage. UFE should be considered for, and discussed with, all appropriate candidates.

Expert Rev. Obstet. Gynecol. 2(5), 621–629 (2007)

Until the late 1990s, the primary reasons for obstetrician–gynecologists to involve interventional radiologists in the care of their patients were focused primarily in two obstetrics and gynaecology (OB/GYN) treatment areas: pelvic/abdominal fluid collections and acute hemorrhage. In his 1995 *Lancet* article, however, Jacques Ravina, a French gynecologist, proposed uterine artery embolization (UAE) as an effective primary fibroid therapy [1]. This significantly changed the interventional radiologist's involvement in women's health, as well as the dynamics of the relationship between the interventional radiologist and the OB/GYN.

Radiologic treatment for OB/GYN-related fluid collections

Radiologic transcuteaneous or transvaginal drainage of pelvic/abdominal fluid collections, including abscesses, has long benefited patients with tubo-ovarian abscesses (TOAs) and the postoperative woman. The advantage to the patient is the avoidance of a major operative surgical procedure, usually requiring an exploratory laparotomy. Especially in the presence of an infectious process, image-guided drainage may not only avoid the need for a large abdominal incision, but may also minimize the potential morbidity of worsening

infection, bleeding, bowel injury or adhesion formation. Personally, I almost always first consider radiologic drainage for both TOAs and postoperative abscesses nonresponsive to antibiotic therapy. Before a surgical approach, while not all patients with TOAs or postsurgical intra-abdominal abscesses are judged to be candidates for radiologic drainage, a consult for such an intervention should be considered. In addition, while image-guided drainage in such scenarios is not always effective, with some patients still requiring a trip to the operating room, in my opinion, the fact that its risk is much less than that of open surgery makes it an often excellent first-line choice of interventional treatment for an otherwise stable patient.

Radiologic treatment for OB/GYN-related hemorrhage

Embolization aimed at stopping bleeding in the acute setting may be a uterine-sparing and potentially life-saving treatment option for both gynecologic and obstetric patients. For gynecologic patients, the most common scenario would be the postsurgical patient with declining hemoglobin levels in the first 24 h postoperatively. A specific example might be the woman with delayed arterial bleeding at the cervical stump following hysterectomy.

CONTENTS

Radiologic treatment for OB/GYN-related fluid collections

Radiologic treatment for OB/GYN-related hemorrhage

Uterine fibroid embolization as a primary fibroid treatment

Uterine fibroid embolization & fertility

Uterine fibroid embolization as a premyomectomy/hysterectomy treatment adjuvant

Economics

Expert commentary

Five-year view

Information resource

Financial disclosure

Key issues

References

Affiliation

Jefferson Medical College,
Department of Obstetrics and
Gynecology, The Benjamin
Franklin House,
834 Chestnut Street, Suite 400,
Philadelphia, PA 19107, USA
Tel.: +1 215 915 4055
Fax: +1 215 955 5041
jaygoldbergmnd@yahoo.com

KEYWORDS:

fibroid, interventional radiology,
uterine fibroid embolization,
women's health

Selective arterial embolization may be preferable to surgical reexploration to both identify the origin of and treat the bleeding. This approach may be especially desirable in the patient with complicated medical conditions, extensive adhesive disease or with bleeding that might be difficult to control surgically, such as in the space of Retzius following a Burch procedure for urinary incontinence. Postcesarean delivery patients may benefit similarly from selective embolization in the same clinical situation of declining hemoglobin levels thought to be due to arterial bleeding soon after delivery.

The more common scenario in obstetrics when embolization might be considered, however, is the patient with immediate postpartum uterine hemorrhage following vaginal delivery, usually caused by uterine atony, that has been nonresponsive to the usual interventions of uterine massage, uterotonic medications (pitocin, carboprost tromethamine, misoprostol and/or methyl-ergonovine) and, possibly, uterine curettage. Rather than proceeding directly to laparotomy for the specific purpose of obtaining surgical access for uterine artery ligation, uterine compression suturing (B-Lynch), hypogastric artery ligation (rarely performed and not a currently recommended intervention) or hysterectomy, the obstetrician may attempt uterine packing followed by UAE. It is important to note that uterine packing in this scenario is controversial. The uterus is packed tightly with gauze placed transcervically until it leads to compression hopefully sufficient to stop or significantly decrease bleeding. A decision must then be made whether to just observe the patient, during which time blood products might be given, depending upon the hemodynamic stability, estimated blood loss and initial blood count, or whether to proceed with UAE. The goal of embolization of both uterine arteries for such a patient would be to decrease overall uterine perfusion and arterial pressure by blocking the major blood supplies, hopefully leading to decreased uterine bleeding. Collateral blood supply to the uterus almost always supplies perfusion sufficient to prevent uterine necrosis.

A prospective study of 27 women with life-threatening postpartum hemorrhage treated with arterial embolization was reported by Pelage and colleagues. All patients had failed uterine packing and medical therapy. The mean hemoglobin level prior to embolization was 7.48 g/dl. All patients had immediate improvement in bleeding, while two required repeat embolization. No major complications occurred. Normal menstruation resumed in all patients, except for two who had undergone cesarean hysterectomy prior to being embolized. The authors concluded that emergency arterial embolization is a safe and effective treatment option [2]. A comprehensive literature review by Vedantham and colleagues of UAE for pelvic hemorrhage, reported that its benefits included a low complication rate, avoidance of surgical risks, fertility preservation and shorter duration of hospitalization. Their review of the literature suggested that embolization should be used before surgical treatment of nonmalignant pelvic bleeding in many clinical settings. Despite UAE being highly effective and relatively noninvasive, the authors felt that the approach was underutilized [3].

In theory, embolization of the uterine arteries in the postpartum patient bleeding from a nonresponsive uterine atony sounds like a better option than laparotomy and vessel ligation or hysterectomy; however, there are several factors that may limit the clinical effectiveness and practicality of this technique. Most obstetric departments do not have the fluoroscopy equipment necessary for embolization, requiring an often hemodynamically unstable patient to be transferred to another area of the hospital. If the patient becomes increasingly unstable during transportation or in the radiology suite, this could be a potential disaster. In addition, with most births occurring after usual work hours or at weekends, an interventional radiologist may not be readily available, thus delaying the embolization. In the severe case of postpartum uterine atony not responding to the embolization attempt, surgical intervention is further delayed with additional blood loss, putting the patient at greater risk for disseminated intravascular coagulopathy, hemorrhagic shock and death. Patients who are hemodynamically unstable are usually best served by being taken to the operating room quickly. Furthermore, not all patients are candidates for this type of intervention. Most interventional radiologists prefer the patient to have an International Normalized Ratio of less than two, often requiring time to sufficiently replace blood products. Even in postpartum patients with bleeding successfully abated following bilateral UAE, there may be significant morbidity. A patient recently treated at Thomas Jefferson University Hospital, (PA, USA) for a severe uterine atony developed sepsis due to complete uterine necrosis, which was diagnosed 2 weeks following UAE, requiring hysterectomy. The majority of patients stable enough to be transferred to the radiology suite for the embolization procedure could probably have been treated sufficiently with uterine packing and blood transfusion alone. Obviously, it would be impossible to have the power sufficient for a randomized trial assessing the added benefit of UAE added to uterine packing in severe postpartum uterine atony.

An additional consideration for the obstetrician/gynecologist is that a patient who requires an exploratory laparotomy to correct a surgical complication, either obstetric or gynecologic, will be much more likely to file a law suit than one whose condition was effectively treated by minimally invasive transcutaneous or transvaginal techniques performed by an interventional radiologist.

Also reported in the literature, but rarely utilized, is embolization for OB/GYN conditions such as gestational trophoblastic disease, ectopic and cervical pregnancy and pelvic malignancy.

Uterine fibroid embolization as a primary fibroid treatment

Uterine fibroids are the most common tumors of the female reproductive tract, occurring in 20–70% of women between 30 and 50 years of age. Black women are most frequently affected, while caucasians, Asians and Scandinavians have lower incidences. Tumor size varies widely and many women have multiple fibroids. Patients may be asymptomatic, with diagnosis following palpation of a firm, enlarged uterus on routine

examination or upon an incidental finding at imaging. Others may present with symptoms such as menorrhagia, intermenstrual bleeding, pelvic pain/pressure, dyspareunia, urinary frequency, abdominal distension, infertility and pregnancy complications. Given the nature and severity of these symptoms, fibroids can have a significant impact on quality of life [4].

Most symptomatic women eventually seek medical treatment. There are many fibroid treatments available, their selection based on many factors, including bulk symptoms, bleeding symptoms and desire for future fertility/uterine preservation. A woman's ultimate treatment choice also depends on the fibroid-related impact on the quality of her life, acceptable length of convalescence, and the values that she assigns to tolerable invasiveness and symptom resolution (FIGURE 1).

Medications used to treat fibroids include analgesics, usually NSAIDs, and combination estrogen/progestin oral contraceptives. Gonadotropin-releasing hormone agonists (e.g., leuprolide) can temporarily reduce fibroid volume by up to 40%, while also decreasing vaginal bleeding [5]. However, their significant side-effect profile (e.g., vasomotor instability, mood swings and bone loss) and the fibroids' quick return to baseline upon discontinuation of therapy primarily restrict use to temporary tumor reduction prior to surgery.

Women with symptomatic uterine fibroids refractory to medical management have traditionally undergone surgical resection via hysterectomy or myomectomy. In the USA, approximately 250,000 women undergo hysterectomy annually for symptomatic fibroids, with approximately 35,000 undergoing myomectomy. While preserving the uterus, many women undergoing myomectomy may require additional procedures owing to persistent symptoms or the growth of new fibroids. The desire for uterine/fertility preservation and avoidance of surgery has increased the demand for alternative treatments. Uterine fibroid embolization (UFE) has emerged over the last decade as an increasingly popular and effective nonsurgical option. In its first decade of usage, UFE has treated approximately 150,000 women with symptomatic fibroids worldwide. It is estimated that approximately 40,000 additional women will undergo treatment in 2007 (25,000 in the USA and 15,000 elsewhere) [GARY SAXTON, BIOSPHERE MEDICAL, INC., PERS. COMM.].

Pre-UFE evaluation considerations

Before referral to an interventional radiologist, the preoperative work-up should comprise a thorough history and physical/gynecologic examination, as well as a discussion of UFE and alternatives. A pregnancy test should be performed early in the assessment. The patient should also undergo endometrial biopsy to exclude hyperplasia or cancer, although this may be optional in women without abnormal bleeding.

Pelvic images should be obtained via ultrasonography or MRI. While most gynecologists initially order a pelvic ultrasound, many interventional radiologists additionally require a pre-evaluation pelvic MRI. Their rationale has been that the MRI better differentiates fibroids from adenomyosis, which does not respond as well to UAE, and from leiomyosarcomas.

As discussed below, in patients who have already undergone ultrasound, pre-UFE MRI may not be clinically necessary, with increasing healthcare costs.

Adenomyosis often clinically mimics the bulk and bleeding symptoms of uterine fibroids. It affects the uterus diffusely and globally, causing a thickened, hypertrophied myometrium. In patients failing medical therapy, the only treatment has been hysterectomy. A recent study of UAE for symptomatic adenomyosis reported that 73% of patients had improvement in menorrhagia at 1 year, but by 2 years 44% needed additional treatment, including 28% undergoing hysterectomy [6]. Thus, obstetrician-gynecologists have a treatment to offer patients with adenomyosis that will treat over 50% of patients successfully, allowing a significant number to avoid hysterectomy. UAE may be especially valuable in the subsets of patients with symptomatic adenomyosis desiring future fertility who have increased surgical risk due to adhesive disease, or those absolutely desiring uterine preservation. Patients should be counseled that the presence of adenomyosis significantly decreases the efficacy of UFE performed to treat coexisting fibroids [7].

It is very difficult to diagnose a leiomyosarcoma in the absence of a surgical specimen. Delayed diagnosis of four uterine sarcomas has been reported in the approximately 150,000 UFEs performed to date (0.003%) [8]. A rapid increase in the size of the uterus, especially after menopause, raises suspicion. However, Parker and colleagues found only a 0.27% incidence in 371 women undergoing hysterectomy for suspected leiomyosarcoma. Endometrial biopsy, carried out as part of the routine pre-embolization work-up, largely excludes endometrial cancer; however, its sensitivity in detecting leiomyosarcoma is less than 25% [9].

Currently, there is no imaging standard used to identify sarcomas prior to UAE. Research studies with small sample sizes evaluating the ability to detect sarcomas using modalities such as transvaginal color and pulsed Doppler sonography, MRI and PET, which had initially positive results, have not proved to be efficacious or utilized in the clinical setting [10–12]. An informal survey, performed by the author, of several interventional radiologists, with a combined experience of more than 4000 UFEs, did not find a single sarcoma detected by routine MRI.

It is important to remember that many women thought to have symptomatic fibroids are expectantly managed, with a small percentage of those actually having sarcoma. In these patients, the diagnosis of sarcoma would only occur after they eventually underwent hysterectomy or myomectomy or developed metastatic disease.

Clinical efficacy of UFE

UFE has been shown to be an effective and safe treatment for symptomatic uterine fibroids. Spies and colleagues prospectively studied 200 consecutive women undergoing UFE. They reported improvement in heavy bleeding in 90% of cases (95% confidence interval [CI]: 86–95%) and improvement in bulk symptoms in 91% (95% CI: 86–95%) at 1 year. In total, 11% of patients (95% CI: 7–15%) underwent subsequent

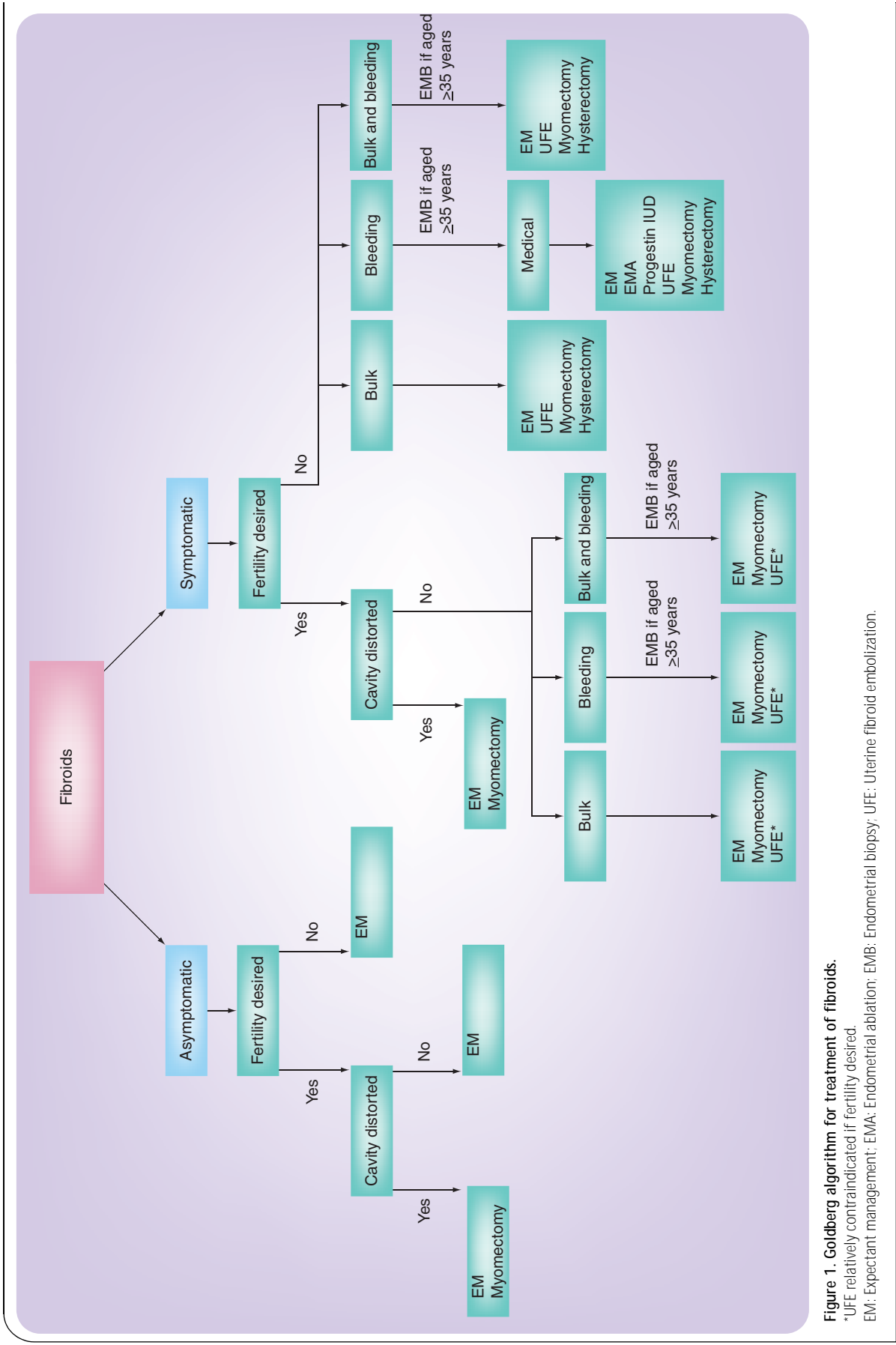


Figure 1. Goldberg algorithm for treatment of fibroids.

*UFE relatively contraindicated if fertility desired.

EM: Expectant management; EMA: Endometrial ablation; EMB: Endometrial biopsy; UFE: Uterine fibroid embolization.

gynecologic intervention during the 12-month follow-up period [13]. Similarly, the Ontario Uterine Fibroid Embolization Trial, a prospective, multicenter study, observed reductions in the median uterine and dominant fibroid volume of 35 and 42% following UFE, respectively. A total of 91% of the 583 patients expressed satisfaction with their procedure, including significant improvements for menorrhagia (83%), dysmenorrhea (77%) and urinary complaints (86%) [14]. A multicenter prospective cohort study evaluated women undergoing UFE (n = 102) and hysterectomy (n = 50) for symptomatic fibroids. The mean uterine volume was 1.8-times greater for patients undergoing UFE. There were significant improvements in symptoms and quality of life scores in both groups. Overall morbidity occurred more frequently in women in the hysterectomy group compared with the UFE group (34 vs 14.7%; p = 0.01). In this study, the three patients who had serious complications were in the hysterectomy group [15].

A 2006 Cochrane Review concluded that UAE offers the advantage over surgery of a quicker return to routine activities. Following discharge, after UAE there were higher rates of minor complications, office visits and readmissions. There was no evidence of benefit in terms of satisfaction compared with surgery (TABLE 1) [16].

The Randomized trial of Embolization versus Surgical Treatment for fibroids Trial randomized patients to UFE or surgery (patient choice of hysterectomy or myomectomy). Quality of life scores were similar at 1 year. Patients who underwent UFE returned to work sooner; after 20 days versus 62 days. In total, 12% of the UFE group reported complications, including one adrenal and two breast cancers that were not thought to be related to the treatment. A total of 20% of the surgical group reported complications, including two operative hemorrhages, two anesthesia complications, four wound problems and one patient with prolonged urinary retention. In total, 9% of patients in the UFE group had a repeat UFE or surgery at 1 year. The authors' conclusion was that the faster recovery after UFE must be weighed against the risk for retreatment [17].

The Embolization versus hysterectomy (EMMY) trial was a Dutch prospective randomized trial of 177 patients randomized to either UAE or hysterectomy for symptomatic fibroids. Short-term data (6 weeks) found similar rates of major complications.

Patients treated with UAE had more minor complications (58 vs 40%; p = 0.024), more readmissions (11 vs 0%; p = 0.003) but shorter length of stay (2.5 vs 5.1 days; p < 0.001) [18]. Another publication from the EMMY trial reported on postprocedural pain and return to daily activities. Patients treated with UAE had less pain in the first 24 h (p = 0.012) and returned to work sooner (28.1 vs 63.4 days; p < 0.001) compared with those who underwent hysterectomy [19].

Recently, several studies of long-term outcomes (of 5 years or more) have shown UFE to have good durability. Pooled data from three studies of 434 patients show that 77% had no fibroid symptoms and only 17% required another fibroid intervention at 5–7 years following UFE (TABLE 2) [20–22]. In terms of durability, myomectomy has been shown to have a lower failure rate, defined as needing another surgery or embolization within 3–5 years, of only 3 versus 29% for UFE [23].

Additional data on UFE's long-term efficacy and safety is currently and will continue to be published from the UAE Fibroid Registry for Outcomes Data project, a longitudinal study developed by the Society of Interventional Radiology following UFEs performed at 72 centers, which enrolled more than 3000 patients. This is the largest prospective fibroid study ever performed, although unfortunately no similar studies of myomectomy or hysterectomy exist in the OB/GYN literature for comparison.

Complications

Most patients report some degree of 'postembolization syndrome,' characterized by low-grade fever, pain, malaise, nausea and leukocytosis, generally within the first 4 days. This may be caused by the systemic effects of transient fibroid and uterine ischemia. Although the condition is usually self-limiting and observable on an outpatient basis, these patients are often admitted for antibiotic therapy.

Spies and colleagues prospectively studied 400 consecutive patients, finding that major complications occurred in 0.5% of embolizations performed for symptomatic fibroids, including pulmonary embolism, arterial thrombosis, groin hematomas, local infection, guide-wire perforation of arteries, allergic reaction to contrast medium, endometritis, ischemia of pelvic organs, sepsis and death [24]. Among more than

Table 1. Major advantages and disadvantages of uterine fibroid treatments.

| Treatment | Advantages | Disadvantages |
|------------------------------|--|---|
| Hysterectomy | Definitive therapy End of menses | 4–6-week recovery Loss of fertility Higher complication rate |
| Myomectomy | Future fertility Uterine preservation | 4–6-week recovery Higher complication rate |
| Uterine fibroid embolization | 7–10-day recovery Lower complication rate Uterine preservation | Increases future pregnancy risks Higher treatment failure rate No outcomes data > 5 years |

Table 2. Published long-term data for uterine fibroid embolization.

| | Length of follow-up (years) | Patients completing follow-up | Asymptomatic (%) | Additional procedures | Ref. |
|-------------------------|-----------------------------|-------------------------------|------------------|--|------|
| Spies <i>et al.</i> | 5 | 182/200 | 73 | 25 hysterectomies Eight myomectomies Three repeat UFEs | [20] |
| Walker and Barton-Smith | 5–7 | 172/258 | 75 | Nine hysterectomies Six myomectomies Nine hysteroscopic resections One endometrial ablation Three hysteroscopies | [21] |
| Katsumori <i>et al.</i> | 5 | 80/96 | 90 | 10% | [22] |
| Total | 5–7 | 434/554 | 77 | 17% | |

UFE: Uterine fibroid embolization.

150,000 procedures performed worldwide to date, there were four related fatalities. In two cases, pulmonary embolism occurred within a few days of the procedure; the two other deaths occurred within 2 weeks and were related to septicemia and disseminated intravascular coagulation [25].

There have been reports of total uterine necrosis, transient and permanent ovarian failure, and external sexual dysfunction. These complications may occur up to 2 years after the procedure. Nontarget vascular embolizations of the gluteus muscle, ovaries, labia minora and bladder wall also have been noted.

When viewed in the context of the large number of procedures performed – and considering the complications associated with myomectomy and hysterectomy – these rare complications show that, overall, UAE is a very safe procedure [26].

Uterine fibroid embolization & fertility

Whether UFE should be performed in women desiring future fertility has been a much debated question, both between obstetrician–gynecologists and radiologists and within the radiology community itself. Our series, published in *Obstetrics & Gynecology* in 2002, was the first to calculate risks associated with pregnancies following UFE. Its most clinically important finding was an increased rate of preterm delivery compared with the general population [27]. In a follow-up study comparing pregnancy outcomes following UFE and laparoscopic myomectomy, we also found an increased rate of preterm delivery following UFE, while the rate following laparoscopic myomectomy was no higher than in the general population [28].

More recent studies have also reported increased rates of preterm delivery following UFE. Walker and McDowell reported on 56 pregnancies following 1200 UAEs performed by a single interventional radiologist identified retrospectively. A total of 59% resulted in live deliveries, with an 18% rate of preterm delivery. In addition, 30.4% of pregnancies miscarried, 72.7% were delivered via cesarean and 18.2% had postpartum hemorrhage. All of these complication rates were more common following UAE than in the general obstetrical population [29]. Carpenter and Walker reported on 29 pregnancies identified retrospectively

in 671 women following UAE. 27% had spontaneous abortions. Of 16 deliveries after 24 gestational weeks, 25% had preterm deliveries. A total of 88% of births were via cesarean delivery. The rate of postpartum hemorrhage was 20%. The authors concluded that, other than the increased cesarean rate, prior UAE does not appear to cause any other major excess obstetrical-associated risk [30].

The reason for the increased rate of preterm delivery following UFE is not known, but may involve the persistence of fibroids or the effect of UFE on factors involved in the labor cascade. Additionally, there are no studies available with sufficient power to reliably calculate pregnancy rates following UFE. The American College of Obstetricians and Gynecologists, while presenting a much more positive attitude towards UFE in Committee Opinion #293 (February 2004), regards the technique as relatively contraindicated for women desiring future fertility for the aforementioned reasons [31].

Although the rates of preterm delivery following UFE were elevated in these studies, the rates of very premature preterm delivery (<32 weeks) were low and most pregnancies did well overall. The limited number of these pregnancies following UFE has not allowed subanalysis to determine which fibroid characteristics are most important in evaluating whether UFE is a good option for certain fertility-desiring patients. A similar criticism can be made about the literature for myomectomy. Examination of the reproductive endocrinology literature may help to answer the important question of whether UFE may place women at risk for lower pregnancy and/or higher miscarriage rates.

From studies of women undergoing IVF, it has been shown that fibroids which distort the endometrial cavity decrease pregnancy rates. A meta-analysis by Donnez and Jadoul of six studies demonstrated that women with submucosal and intramural fibroids distorting the uterine cavity undergoing IVF had lower pregnancy rates (6 out of 65 women; 9%) compared with women with fibroids not distorting the cavity (163 out of 487; 34%) and women without fibroids (661 out of 1636; 405%) [32]. Another study by Benson and colleagues

of first trimester pregnancies with cardiac activity seen on ultrasound found that women with multiple fibroids had higher rates of spontaneous abortion (24%) compared with those with only a single fibroid or no fibroids (8%) [33]. It may be inferred that the patients with multiple fibroids were also more likely to have distorted uterine cavities.

While myomectomy removes fibroids, reconstructing normal uterine anatomy, UFE merely decreases fibroid volume. Thus, in a woman with multiple fibroids distorting her cavity, following UFE her fibroids may be smaller, but will still distort her cavity. This, in theory, will potentially lead to subfertility due to lower pregnancy and higher miscarriage rates in women desiring future fertility following UFE. Thus, for women desiring future fertility, while it may be reasonable to offer UFE to those with a non-distorted uterine cavity, those with distorted cavities should be advised to undergo myomectomy. In addition, UFE may be considered particularly in certain patients desiring fertility, such as those who have previously undergone myomectomy or who have extensive pelvic adhesions, morbid obesity, those who refuse blood products, and those with surgical risks. Patients must also weigh up the longer convalescence following myomectomy and the increased surgical risks, including bleeding, infection, adhesions, anesthesia risks and damage to internal structures, when making decisions regarding fertility.

Uterine fibroid embolization as a premyomectomy/hysterectomy treatment adjuvant

Ravina initially used UFE as a preoperative treatment prior to myomectomy in massively enlarged uteri (>20 weeks' size) in an attempt to decrease the risk of hemorrhage [1]. UFE performed several weeks prior to myomectomy both reduces fibroid volume and decreases vascularity. Ravina noted that several women cancelled their scheduled surgery after receiving satisfactory symptom relief in the interval between the premyomectomy UFE and the day of surgery. This led to his study of UFE as a primary fibroid therapy.

Obstetrician-gynecologists are familiar with the benefits of preoperative gonadotropin-releasing hormone (GnRH) agonist therapy to decrease surgical risk during myomectomy or hysterectomy for large fibroid uteri. While temporarily decreasing uterine volume by up to 40%, GnRH agonist therapy requires 3 months for maximum benefit, is expensive and has significant and unpleasant side effects from the induced menopausal state.

Premyomectomy UFE is currently an underutilized surgical adjuvant that can decrease the risk from the massively enlarged fibroid uterus. These benefits, especially the decreased risk of intraoperative hemorrhage, may also outweigh potential risks in women desiring future fertility. The optimal interval for performing myomectomy following adjuvant UFE remains to be established. Compared with GnRH agonist therapy, the interval until surgery is much shorter and the systemic side effects are avoided. Premyomectomy UFE does confer substantial additional cost – for example; a 48% increase from US\$5676 for a myomectomy alone to \$8383 in Philadelphia (PA, USA).

However, these expenses must be weighed against the potential savings via complication reduction in this high-risk subgroup of patients with massively enlarged uteri [34].

Economics

There is at present a financial 'turf war' between gynecologists and interventional radiologists regarding the treatment of fibroids. With 250,000 women undergoing hysterectomy each year, primarily for uterine fibroids, in addition to the large number undergoing myomectomy, the relative number of UFE procedures has remained relatively low, with only 5–8% growth per year recently. Much recent media attention has focused on this issue. *The Wall Street Journal* published a front page article insinuating that the primary reason that gynecologists, often acting as a 'gate keepers', were not referring or even discussing the option of UFE with appropriate patients was due to financial self-interest [35]. While this negative insinuation may unfortunately be true for a few gynecologists, there are certainly other factors contributing to gynecologists previously not discussing UFE with patients being offered myomectomies or hysterectomies for fibroids. Many Obstetrician-gynecologists, as well as primary-care physicians, were previously unfamiliar with the procedure, may have had misconceptions regarding the risks and potential candidates or may have been awaiting long-term outcomes data [26]. Additionally, the gynecology community was initially deterred by many interventional radiologists not taking proper responsibility for early UFE complications and the cavalier approach of interventional radiologists in recommending UFE for patients desiring future fertility.

In response to the gatekeeper issue, UFE has become a procedure that is marketed heavily by interventional radiologists directly to the public through the internet and print media as an increasingly popular, safe, nonsurgical alternative to myomectomy and hysterectomy. Most women undergoing UFE continue to be self-referrals to interventional radiologists or are referred by their gynecologist or primary-care physician only after specifically inquiring about the procedure.

Over the past 2–3 years, it has been my experience that UFE is becoming more accepted and increasingly offered to patients by gynecologists as a mainstream treatment option for appropriate candidates. Especially given the recent long-term outcomes data, a proper informed consent for patients being offered myomectomy or hysterectomy should also include the option of UFE unless otherwise contraindicated [36–38].

Expert commentary

The role of the interventional radiologist in women's health has recently expanded from primarily draining pelvic/abdominal fluid collections and embolizing acute obstetrical and gynecologic hemorrhage to also providing a primary treatment for symptomatic uterine fibroids. As an increasingly utilized alternative to hysterectomy and myomectomy, UFE is safe and effective for improving bleeding and bulk symptoms in most patients with symptomatic uterine fibroids. In addition to uterine preservation, UFE offers the benefits of avoidance of

surgery, shorter duration of hospitalization, decreased morbidity, quicker return to work and potential financial savings for the health-care system. Not all fibroids are best treated with UFE. Myomectomy may be a better option in the woman desiring future fertility, especially if fibroid-related distortion of the uterine cavity is present.

Five-year view

As additional studies on clinical outcomes following UFE are published, especially long-term data, the standing of this technique as a mainstream treatment option will be reinforced. Given its economic savings for the insurer and quicker return to work when compared with hysterectomy and myomectomy, pressure will be placed upon obstetrician-gynecologists by the

insurer to include UFE in their counseling for appropriate women. As both patients and obstetrician-gynecologists become more familiar with the benefits of UFE, its utilization will continue to increase.

Information resource

For additional embolization and fibroid educational information and images, please visit the website of the Jefferson Fibroid Center:

www.jeffersonhospital.org/fibroid.

Financial disclosure

Goldberg is a consultant for Repros Therapeutics, Inc., TX, USA and BioSphere Medical, Inc., MA, USA.

Key issues

- Until the late 1990s, the primary reasons for obstetrician/gynecologists to involve interventional radiologists in the care of their patients were for pelvic/abdominal fluid collections and acute hemorrhage.
- Jacque Ravina, a French gynecologist, proposed uterine fibroid embolization (UFE) as an effective primary fibroid therapy in 1995.
- Approximately 150,000 UFEs have been performed over the past decade.
- UFE improves bleeding and bulk symptoms, with good durability in long-term studies (5 years).
- Morbidity with UFE is approximately half that of hysterectomy.
- Pregnancies conceived following UFE have an increased risk of complications including preterm delivery, especially in those women with distorted uterine cavities.
- Patients requiring treatment who desire future fertility, especially those with distorted uterine cavities, are best served with myomectomy.
- Premyomectomy UFE for the massively enlarged uterus may decrease the surgical risk of hemorrhage.
- A fibroid treatment algorithm based on symptoms, desire for fertility and cavity distortion is introduced.
- UFE should be considered for, and discussed with, all appropriate candidates.

References

Papers of special note have been highlighted as:

• of interest

•• of considerable interest

- 1 Ravina JH, Herbreteau D, Ciraru-Vigneron N *et al*. Arterial embolisation to treat uterine myomata. *Lancet* 346(8976), 671–672 (1995).
- 2 Pelage JP, Dref OL, Mateo J *et al*. Life-threatening primary postpartum hemorrhage: treatment with emergency selective arterial embolization. *Radiology* 208, 359–362 (1998).
- 3 Vedantham S, Goodwin SC, McLucus B, Mohr G. Uterine artery embolization; an underused method of controlling pelvic hemorrhage. *Am. J. Obstet. Gynecol.* 176, 938–948 (1997).
- 4 Goldberg J. Uterine artery embolization for symptomatic leiomyomata. *Female Patient* 31, 45–50 (2006).
- 5 Friedman AJ, Hoffman DI, Comite F, Browneller RW, Miller JD. Treatment of leiomyomata uteri with leuprolide acetate depot: a double-blind, placebo-controlled, multicenter study. The Leuprolide Study Group. *Obstet. Gynecol.* 77(1), 720–725 (1991).
- 6 Pelage JP, Jacob D, Fazel A *et al*. Midterm results of uterine artery embolization for symptomatic adenomyosis: initial experience. *Radiology* 234, 948–953 (2005).
- 7 Goldberg J. Uterine artery embolization for adenomyosis: looking at the glass half full. *Radiology* 236(3), 1111–1112 (2005).
- 8 Goldberg J, Burd I, Price FV, Worthington-Kirsch R. Leiomyosarcoma in a pre-menopausal patient following uterine artery embolization. *Am. J. Obstet. Gynecol.* 191, 1733–1735 (2004).
- 9 Parker WH, Fu YS, Berek JS. Uterine sarcoma in patients operated on for presumed leiomyoma and rapidly growing leiomyoma. *Obstet. Gynecol.* 83(3) 414–418 (1994).
- 10 Kurjak A, Kupesic S, Shalan H, Jukic S, Kosuta D, Ilijas M. Uterine sarcoma: a report of 10 cases studied by transvaginal color and pulsed Doppler sonography. *Gynecol. Oncol.* 59, 342–346 (1995).
- 11 Pattani SJ, Kier R, Deal R, Luchansky E. MRI of uterine leiomyosarcoma. *Magn. Reson. Imaging* 13, 331–333 (1995).
- 12 Umesaki N, Tanaka T, Miyama M *et al*. Positron emission tomography with ¹⁸F-fluorodeoxyglucose of uterine sarcoma:

- a comparison with magnetic resonance imaging and power Doppler imaging. *Gynecol. Oncol.* 80, 372–377 (2001).
- 13 Spies JB, Ascher SA, Roth AR, Kim J, Levy EB, Gomez-Jorge J. Uterine artery embolization for leiomyomata. *Obstet. Gynecol.* 98(1), 29–34 (2001).
- 14 Pron G, Bennett J, Common A, Wall J, Asch M, Sniderman K. The Ontario Uterine Fibroid Embolization Trial. Part 2. Uterine fibroid reduction and symptom relief after uterine artery embolization for fibroids. *Fertil. Steril.* 79(1), 120–127 (2003).
- 15 Spies JB, Cooper JM, Worthington-Kirsch R, Lipman JC, Mills BB, Benenati JF. Outcome of uterine embolization and hysterectomy for leiomyomas: results of a multicenter study. *Am. J. Obstet. Gynecol.* 191(1), 22–31 (2004).
- 16 Gupta JK, Sinha AS, Lumsden MA, Hickey M. Uterine artery embolization for symptomatic uterine fibroids. *Cochrane Database Syst. Rev.* 1, CD005073 (2006).
- 17 The REST Investigators. Uterine-artery embolization versus surgery for symptomatic uterine fibroids. *N. Engl. J. Med.* 356, 360–370 (2007).
- 18 Hehenkamp WJK, Volkers NA, Donderwinkel PFJ *et al.* Uterine artery embolization versus hysterectomy in the treatment of symptomatic uterine fibroids (EMMY trial): peri- and post-procedural results from a randomized controlled trial. *Am. J. Obstet. Gynaecol.* 193, 1818–1829 (2005).
- **Prospective trial that randomized patients with symptomatic fibroids to uterine artery embolization or surgery.**
- 19 Hehenkamp WJK, Volkers NA, Birnie E, Reekers JA, Ankum WM. Pain and return to daily activities after uterine artery embolization and hysterectomy in the treatment of symptomatic uterine fibroids: results from the randomized EMMY trial. *Cardiovasc. Intervent. Radiol.* 29, 179–187 (2006).
- 20 Spies JB, Bruno J, Czeyda-Pommersheim F, Magee ST, Ascher SA, Jha RC. Long-term outcome of uterine artery embolization of leiomyomata. *Obstet. Gynecol.* 106, 933–939 (2005).
- **Clinical outcomes following uterine fibroid embolization at 5 years.**
- 21 Walker WJ, Barton-Smith P. Long-term follow up of uterine artery embolisation – an effective alternative in the treatment of fibroids. *Br. J. Obstet. Gynaecol.* 113, 464–468 (2006).
- 22 Katsumori T, Kasahara T, Akazawa K. Long-term outcomes of uterine artery embolization using gelatin sponge particles alone for symptomatic fibroids. *Am. J. Roentgenol.* 186, 848–854 (2006).
- 23 Broder MS, Goodwin S, Chen G *et al.* Comparison of long-term outcomes of myomectomy and uterine artery embolization. *Obstet. Gynecol.* 100(5 Pt 1), 864–868 (2002).
- 24 Spies JB, Spector A, Roth A, Baker C, Mauro L, Murphy-Skrynarz K. Complications after uterine artery embolization for leiomyomas. *Obstet. Gynecol.* 100(5), 873–880 (2002).
- 25 Pelage JP, Jacob D, Le Dref O, Lacombe P, Laurent A. Fatal sepsis after uterine artery embolization with microspheres. *J. Vasc. Interv. Radiol.* 15, 405–406 (2004).
- 26 Goldberg J, Pereira L, Mude-Nochumson H. Uterine artery embolization for symptomatic fibroids. *OBG Management* 4, 69–79 (2003).
- 27 Goldberg J, Pereira L, Berghella V. Pregnancy after uterine artery embolization. *Obstet. Gynecol.* 100(5 Pt 1), 869–872 (2002).
- 28 Goldberg J, Pereira L, Diamond J *et al.* Pregnancy outcomes following treatment for fibroids: uterine artery embolization versus laparoscopic myomectomy. *Am. J. Obstet. Gynecol.* 191(1), 18–21 (2004).
- **Compares pregnancy outcomes following embolization and myomectomy.**
- 29 Walker WJ, McDowell SJ. Pregnancy after uterine artery embolisation for leiomyomata: a series of 56 completed pregnancies. *Am. J. Obstet. Gynecol.* 195(5), 1266–1271 (2006).
- 30 Carpenter TT, Walker WJ. Pregnancy following uterine artery embolisation for symptomatic fibroids: a series of 26 completed pregnancies. *Br. J. Obstet. Gynaecol.* 112, 321–325 (2005).
- 31 Committee on Gynecologic Practice, American College of Obstetricians and Gynecologists. ACOG Committee Opinion. Uterine artery embolization. *Obstet. Gynecol.* 103(2), 403–404 (2004).
- 32 Donnez J, Jadoul P. What are the implications of myomas on fertility? A need for debate? *Human Reprod.* 17, 1424–1430 (2002).
- 33 Benson CB, Chow JS, Chang-Lee W, Hill JA 3rd, Doubilet PM. Outcome of pregnancies in women with uterine leiomyomas identified by sonography in the first trimester. *J. Clin. Ultrasound* 29(5), 261–264 (2001).
- 34 Goldberg J, Cothran S, Bonn J. Pre-myomectomy uterine fibroid embolization for a massively enlarged fibroid uterus. *Female Patient* 31, 1–3 (2006).
- 35 Etter L. Hysterectomy alternative goes unmentioned to many women. *Wall Street Journal*, August 24, A1 (2004).
- 36 Goldberg J. Uterine fibroid embolization: a hidden alternative? *Obstet. Gynecol. Surv.* 60, 209–210 (2005).
- 37 Goldberg J, Ness A, Fossum G. Does uterine fibroid embolization need to be offered as a treatment alternative? Pros and cons. *Contemp. OB/GYN* 6, 78–84 (2005).
- 38 Wallach EE, Vlahos NF. Uterine myomas: an overview of development, clinical features, and management. *Obstet. Gynecol.* 104, 393–406 (2004).

Affiliation

- *Jay Goldberg, MD, MSCP*
 Director, Jefferson Fibroid Center, Director,
 Division of General Obstetrics and Gynecology,
 Associate Professor, Jefferson Medical College,
 Department of Obstetrics and Gynecology,
 The Benjamin Franklin House,
 834 Chestnut Street, Suite 400, Philadelphia,
 PA 19107, USA
 Tel.: +1 215 915 4055
 Fax: +1 215 955 5041
 jaygoldbergmd@yahoo.com