

# Uterine artery embolization for symptomatic fibroids

Uterine artery embolization is less invasive than hysterectomy or myomectomy and increasingly popular among women. Here, a look at the state of the art.

**W**ith the increasing demand for non-surgical alternatives to hysterectomy or myomectomy for fibroids, uterine artery embolization (UAE) has grown in use and popularity—most patients report a high level of satisfaction after the procedure. UAE has been shown to be safe and effective in selected patients with symptomatic fibroids unresponsive to medical treatment. If they are not contemplating pregnancy and do not have additional pelvic pathology, these women may elect UAE as an appropriate alternative to hysterectomy or myomectomy. This article reviews the indications, contraindications, technique, complications, and outcomes of UAE.

## Background

**M**ost of the 590,000 hysterectomies performed each year in the United States are for symptomatic fibroids, the most common tumors of the female reproductive tract.<sup>1</sup> Although hysterectomy is the definitive treatment, increasing numbers of patients express a desire for alternatives, primarily to preserve the uterus. While myomectomy spares the uterus, as many as 25% of women require another surgery for recurrent symptoms.<sup>2</sup>

■ *Dr. Goldberg is clinical assistant professor, department of obstetrics and gynecology; Dr. Pereira is a fellow, maternal-fetal medicine; and Ms. Mude-Nochumson is a second-year medical student, Jefferson Medical College, Philadelphia, Pa.*

These limitations of the primary surgeries for fibroids have increased the demand for UAE.

Embolization of the uterine arteries has been utilized for more than 20 years to treat pelvic hemorrhage following delivery or abortion, ectopic or cervical pregnancy, gestational trophoblastic disease, or malignancy.<sup>3,4</sup> It was first reported as an effective intervention for fibroids in 1995, when Ravina et al<sup>5</sup> noted that several women with symptomatic leiomyomata who underwent UAE as a pre-hysterectomy treatment had such significant

CONTINUED

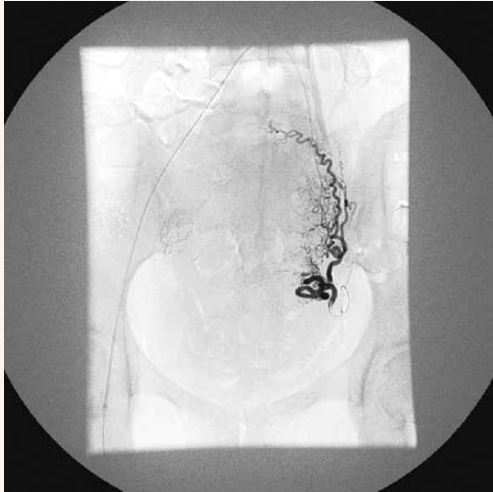
## KEY POINTS

- Uterine artery embolization (UAE) may be especially useful in women who are poor surgical candidates and/or have extensive adhesive disease, or refuse blood products, or are perimenopausal.
- The average reported symptom improvement is 87%; the mean reduction in fibroid volume is 46%.
- Most patients are discharged within 24 hours of the procedure and experience an average recovery period of 8 days.
- Women undergoing UAE for fibroids are more likely than those undergoing myomectomy to need further invasive treatment within 3 to 5 years.
- Although several series and case reports have noted successful pregnancies following UAE, desire for fertility is considered a relative contraindication by some authorities.

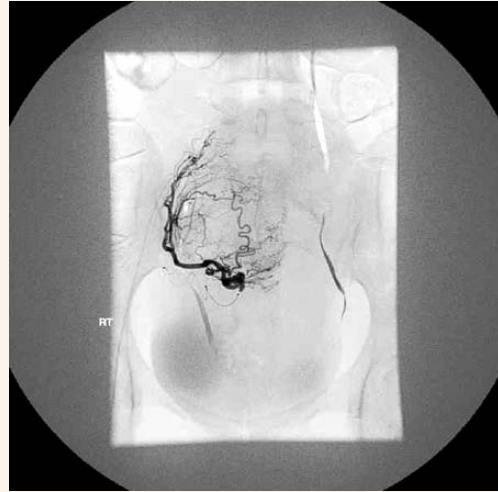
- Uterine artery embolization for symptomatic fibroids

**FIGURE 1**

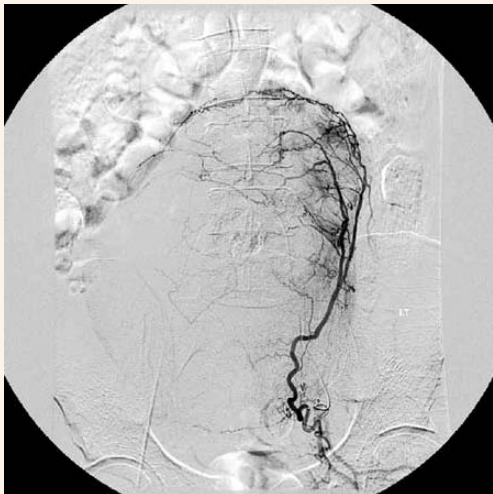
**Arteriograms**



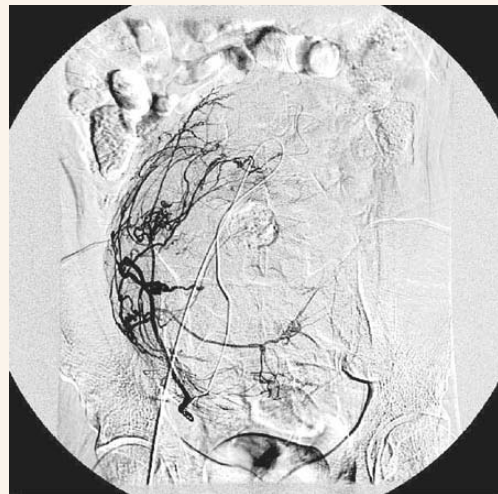
**A.** Please place text.



**B.** Please place text.



**A.** Please place text.



**B.** Please place text.

*Arteriograms courtesy of Joseph Bonn, MD, Interventional Radiology, Thomas Jefferson University Hospital, Philadelphia, Pa.*

CONTINUED





**TABLE****Rates of pregnancy complications after uterine artery embolization (UAE) and in the general population\***

PREGNANCY	COMPLICATIONS OF PREGNANCY % (NUMBER AFFECTED/NUMBER OF SUBJECTS STUDIED)					
	SPONTANEOUS ABORTION	POSTPARTUM HEMORRHAGE	PREMATURE DELIVERY	CESAREAN DELIVERY	SMALL FOR GESTATIONAL AGE	MAL.
After UAE	22 (11/49)	13 (4/31)	28 (9/23)	58 (18/31)	7 (2/29)	17 (5/29)
After UAE for leiomyomata	32 (11/34)	9 (2/23)	22 (5/23)	65 (15/23)	9 (2/22)	22 (5/23)
In the general population	10-15	4-6	5-10	22	10	5

\* Adapted from Goldberg et al.<sup>2</sup>

clinical improvement that hysterectomy was no longer required

In a study involving 200 cases, Spies et al<sup>6</sup> noted improvement in heavy bleeding in 90% (95% confidence interval [CI], 86%, 95%) and a reduction in bulk-related symptoms in 91% (95% CI, 86%, 95%) at 1 year.

On a global level, more than 30,000 UAE procedures have been performed for symptomatic uterine fibroids.

### Economic considerations

A financial turf war of sorts is under way between gynecologists and interventional radiologists regarding the treatment of fibroids. In Philadelphia, Pa, the average reimbursement to an interventional radiologist for a UAE is approximately \$1,650, and

**UAE is increasingly marketed directly to the consumer over the Internet and in print media.**

approximately \$1,000 to a gynecologist for performing a hysterectomy. Consequently, some Ob/Gyns are reluctant to recommend

UAE for their patients, because each referral has a negative impact on their financial bottom line.

Because of this reluctance, UAE is increasingly marketed directly to the consumer over the Internet and in print media. Large proportions of women undergoing UAE are self-referrals or are referred by their gynecologist after specifically requesting the procedure.

UAE may represent a societal savings in terms of direct and indirect costs. For example, a Canadian cost analysis found that UAE was associated with significantly lower hospital costs (\$1007.44 Canadian) than abdominal myomectomy (\$1,781.73 Canadian).<sup>7</sup>

### Technique

UAE is a radiologic procedure performed with either local or regional anesthesia. Most commonly, an approach through the right femoral artery is used, after a preliminary arteriogram (FIGURE 1) to visualize the pelvic vasculature. Fluoroscopic guidance enables a catheter to be passed into the right femoral artery and through the right external iliac artery to the aorta, then down the left common iliac artery to the left internal iliac, down the anterior division, and

CONTINUED

finally to the left uterine artery. When the catheter is properly positioned, polyvinyl alcohol particles or acrylic copolymer beads (300 to 700 microns) are infused until slow flow or stasis occurs in the uterine artery and the fibroid vasculature is occluded (FIGURE 2). The catheter is then pulled back and manipulated into the right uterine artery, which is similarly embolized. Procedure time ranges from 15 to 120 minutes, depending on the patient's anatomy and the skill of the operator.<sup>1,6,8</sup>

### Indications

Like hysterectomy and myomectomy, the indications for UAE are symptomatic fibroids that are unresponsive to medical management. As with myomectomy and hysterectomy, medical management with hormonal agents or analgesics is usually attempted before UAE is considered. Common symptoms of fibroids include abnormal menstrual bleeding, anemia, urinary frequency, dyspareunia, infertility, and abdominal or pelvic pain.

UAE may be an especially useful option for women who are poor surgical candidates and/or have extensive adhesive disease, as well as for those who refuse blood products or are perimenopausal.<sup>6,9,10</sup>

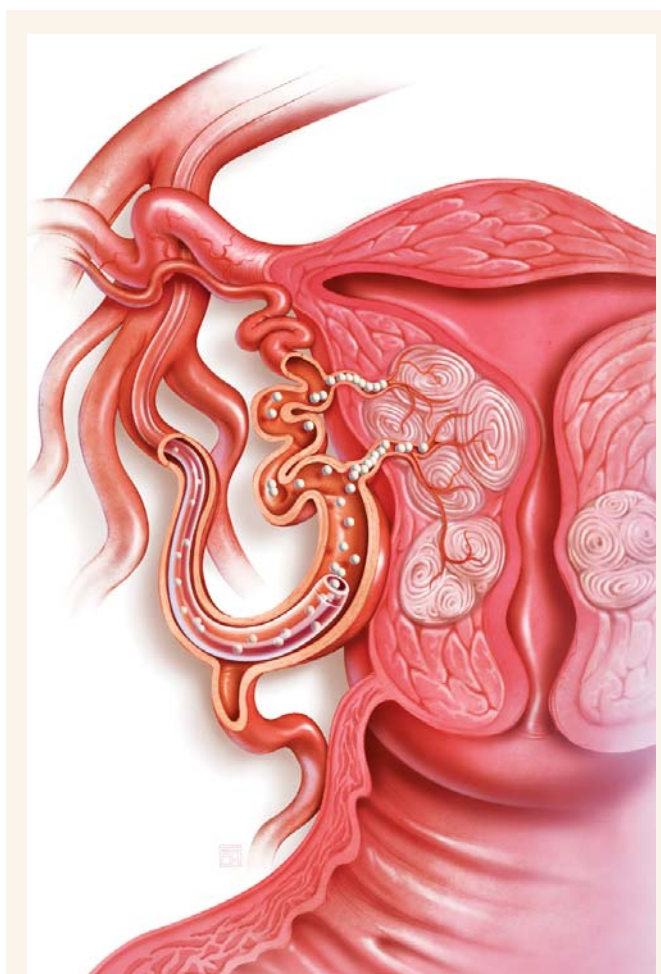
### Contraindications

Pelvic infection, severe contrast allergy, arteriovenous shunting, the presence of an undiagnosed pelvic mass, coagulopathy, renal insufficiency, a history of pelvic radiation, and genital tract malignancy all are contraindications.

Because data are limited on the safety of pregnancy following UAE,

**FIGURE 2**  
UAE Technique

Title



A catheter is passed into the right femoral artery, through the right external iliac artery to the aorta, then down the left common iliac artery to the left internal iliac, down the anterior division to the left uterine artery. Embolization material—polyvinyl alcohol particles or acrylic copolymer beads—is then delivered via catheter in the uterine artery until slow flow or stasis occurs in the artery.

CONTINUED

Please place text.

some authorities consider the desire for future fertility a relative contraindication.<sup>4,8,11</sup>

### Preoperative evaluation

The preoperative workup should include a thorough history and physical examination by both an interventional radiologist and a gynecologist, a pregnancy test, pelvic imaging via ultrasound or MRI, and endometrial biopsy to exclude endometrial hyperplasia or cancer. (Patients without abnormal bleeding may not require an endometrial biopsy.)

### Outcomes

The average reported symptom improvement is 87%, and the mean reduction in fibroid volume is 46%.<sup>1</sup> Most patients see improvement within 3 months of the procedure, with control over the symptoms lasting up to at least 2 years. At 1 year, 90% of patients report improvement in heavy menstrual bleeding.<sup>4</sup> Most patients are discharged within 24 hours of the procedure, compared with 48 to 72 hours for abdominal hysterectomy or myomectomy. They also experience an average recovery period of 8 days, compared with 4 to 6 weeks for abdominal hysterectomy or myomectomy.<sup>6</sup>

However, a recent study found that

**“Post-embolization syndrome” is characterized by low-grade fever, pain, malaise, nausea, and leukocytosis, generally within the first 4 days.**

women undergoing embolization for fibroids were more likely than those undergoing myomectomy to need further invasive treatment (i.e., repeat embolization or surgery) within 3 to 5 years (29% versus 3%).<sup>12</sup>

### Complications

Most patients report some degree of “post-embolization syndrome,” which is characterized by low-grade fever, pain, malaise, nausea, and leukocytosis, generally within the first 4 days.<sup>4</sup> This may be caused by the systemic effects of transient fibroid and uterine ischemia. Although the condition is usually self-limiting and observable on an outpatient basis, these patients are often admitted for antibiotic therapy.

In the most recent series published,<sup>13</sup> major complications occurred in 0.5% of embolizations performed for symptomatic fibroids, including pulmonary embolism, arterial thrombosis, groin hematomas, local infection, guide-wire perforation of arteries, allergic reaction to contrast medium, endometritis, ischemia of pelvic organs, sepsis, and death. Among more than 30,000 procedures performed to date worldwide, there have been 4 related fatalities. In 2 cases, pulmonary embolism occurred within a few days of the procedure; the 2 other deaths occurred within 2 weeks and were related to septicemia and disseminated intravascular coagulation.

There have been reports of total uterine necrosis, transient and permanent ovarian failure, and external sexual dysfunction. These complications may occur up to 2 years after the procedure.<sup>1,4,8,11,14-17</sup> Non-target vascular embolizations of the gluteus muscle, ovaries, labia minora, and bladder wall also have been noted.<sup>18,19</sup>

When viewed in the context of the large number of procedures performed—and considering the complications associated with myomectomy and hysterectomy—these rare complications show that, overall, UAE is a very safe procedure.

### Pregnancy after embolization

Because we lack controlled studies and abundant data, the role of UAE in women contemplating childbearing is unclear. More studies are needed before UAE can be confi-

CONTINUED





dently recommended for these women. Premature ovarian failure is an uncommon but recognized complication of UAE.<sup>14</sup>

Several series and case reports have noted successful pregnancies following UAE.<sup>20,21</sup> Our recent report<sup>22</sup> on 50 pregnancies following UAE for leiomyomata noted higher rates of cesarean delivery, preterm delivery, malpresentation, spontaneous abortion, and postpartum hemorrhage than in the general population (TABLE). It is unclear whether the increased rate of premature delivery and malpresentation is due to residual fibroids, changes in myometrial vascularity or elasticity, or other unknown labor-associated processes.

Pregnancy outcomes following myomectomy have been reported in several case series, with rates of premature delivery and other complications similar to those for the general population.<sup>23,24</sup> Confounding factors (e.g., residual fibroids) and the absence of randomized controlled trials, however, make it difficult to make well-founded comparisons of pregnancy outcomes following UAE and myomectomy.

Theoretical concerns about risk of growth restriction and preeclampsia following UAE have been raised. In our study, we did not calculate an increase of small-for-gestational-age infants following embolization.<sup>22</sup> Uterine rupture during pregnancy after UAE also has been reported.<sup>25</sup> ■

#### INTERNET RESOURCES

**Society of Cardiovascular and Interventional Radiologists** ([www.SCVIR.org](http://www.SCVIR.org))  
**Fibroid Uterine Artery Embolization Registry** ([www.fibroidregistry.org](http://www.fibroidregistry.org))  
**American College of Obstetricians and Gynecologists** ([www.acog.org](http://www.acog.org))

#### REFERENCES

1. Floridon C, Lund N, Thomsen SG. Alternative treatment for symptomatic fibroids. *Curr Opin Obstet Gynecol.* 2001;13:491-495.
2. Stenchever MA, Droegemueller W, Herbst AL, Mishell DR. *Comprehensive Gynecology.* 4th ed. St. Louis: Mosby; 2001.
3. Goodwin SC, Walker WJ. Uterine artery embolization for the treatment of uterine fibroids. *Curr Opin Obstet Gynecol.* 1998;10:315-320.
4. Schwartz ML, Klein A, McLucas B. Using uterine artery embolization to treat fibroids. *Contemporary OB/GYN.* 2001;8:14-37.
5. Ravina J, Herbreteau D, Ciraru-Vigneron N, et al. Arterial embolization to treat uterine myomata. *Lancet.* 1995;346:671-672.
6. Spies JB, Ascher SA, Roth AR, Kim J, Levy EB, Gomcz-Jorge J. Uterine artery embolization for leiomyomata. *Obstet Gynecol.* 2001;98:29-34.
7. Al-Fozan H, Dufort J, Kaplow M, Valenti D, Tulandi T. Cost analysis of myomectomy, hysterectomy, and uterine artery embolization. *Am J Obstet Gynecol.* 2002;187(5):1401-1404.
8. Demello AB. Uterine artery embolization. *AORN J.* 2001;73(4):788-814.
9. Bradley EA, Reidy JF, Forman RG, Jarosz J, Braude PR. Transcatheter uterine artery embolization to treat large uterine fibroids. *Br J Obstet Gynaecol.* 1998;15:235-240.
10. Goodwin SC, Vedantham S, McLucas B, Forno A, Perrella R. Preliminary experience with uterine artery embolization for uterine fibroids. *J Vasc Interv Radiol.* 1997;8:517-520.
11. Godfrey CD, Zbella EA. Uterine necrosis after uterine artery embolization for leiomyoma. *Obstet Gynecol.* 2001;98:950-952.
12. Broder MS, Goodwin S, Chen G, et al. Comparison of long-term outcomes of myomectomy and uterine artery embolization. *Obstet Gynecol.* 2002;100:864-868.
13. Spies JB, Spector A, Roth A, Baker C, Mauro L, Murphy-Skyrynarz K. Complications after uterine artery embolization for leiomyomas. *Obstet Gynecol.* 2002;100(5):873-880.
14. Amato P, Roberts AC. Transient ovarian failure: a complication of uterine artery embolization. *Fertil Steril.* 2001;75(2):438-439.
15. Lai AC, Goodwin SC, Bonilla SM, et al. Sexual dysfunction after uterine artery embolization. *J Vasc Interv Radiol.* 2000;11:755-758.
16. Stringer N. Diagnosis and management of long-term complications of uterine artery embolization. *Female Patient.* 2002;27(11):13-24.
17. Vashisht A, Studd J, Carey A, Burn P. Fatal septicaemia after fibroid embolisation. *Lancet.* 1999;354:307-308.
18. Sultana CJ, Goldberg J, Aizenman L, Chon JK. Vesicouterine fistula after uterine artery embolization: A case report. *Am J Obstet Gynecol.* 2002;187:1726-1727.
19. Yeagley T, Goldberg J, Klein T, Bonn J. Labial necrosis after uterine artery embolization for leiomyomas. *Obstet Gynecol.* 2002;100(5):881.
20. Vashisht A, Smith JR, Thorpe-Beeston G, McCall J. Pregnancy subsequent to uterine artery embolization. *Fertil Steril.* 2001;75(6):1246-1247.
21. Ravina JH, Vigneron NC, Aymard A, Le Dref O, Merland JJ. Pregnancy after embolization of uterine myoma: Report of 12 cases. *Fertil Steril.* 2000;73(6):1241-1243.
22. Goldberg J, Pereira L, Berghella V. Pregnancy after uterine artery embolization. *Obstet Gynecol.* 2002;100(5):869-872.
23. Seracchioli R, Rossi S, Govoni F, et al. Fertility and obstetric outcome after laparoscopic myomectomy of large myomata: A randomized comparison with abdominal myomectomy. *Hum Reprod.* 2000;15(12):2663-2668.
24. Dessolle L, Soriano D, Poncelet C, Benifla JL, Madelenat P, Darai E. Determinants of pregnancy rate and obstetric outcome after laparoscopic myomectomy for infertility. *Fertil Steril.* 2001;76(2):370-374.
25. Walker W, Green A, Sutton C. Bilateral uterine artery embolization for myomata: Results, complications, and failures. *Min Invas Ther Allied Technol.* 1999;8(6):449-454.

The authors report no financial relationships with any companies whose products are mentioned in this article.